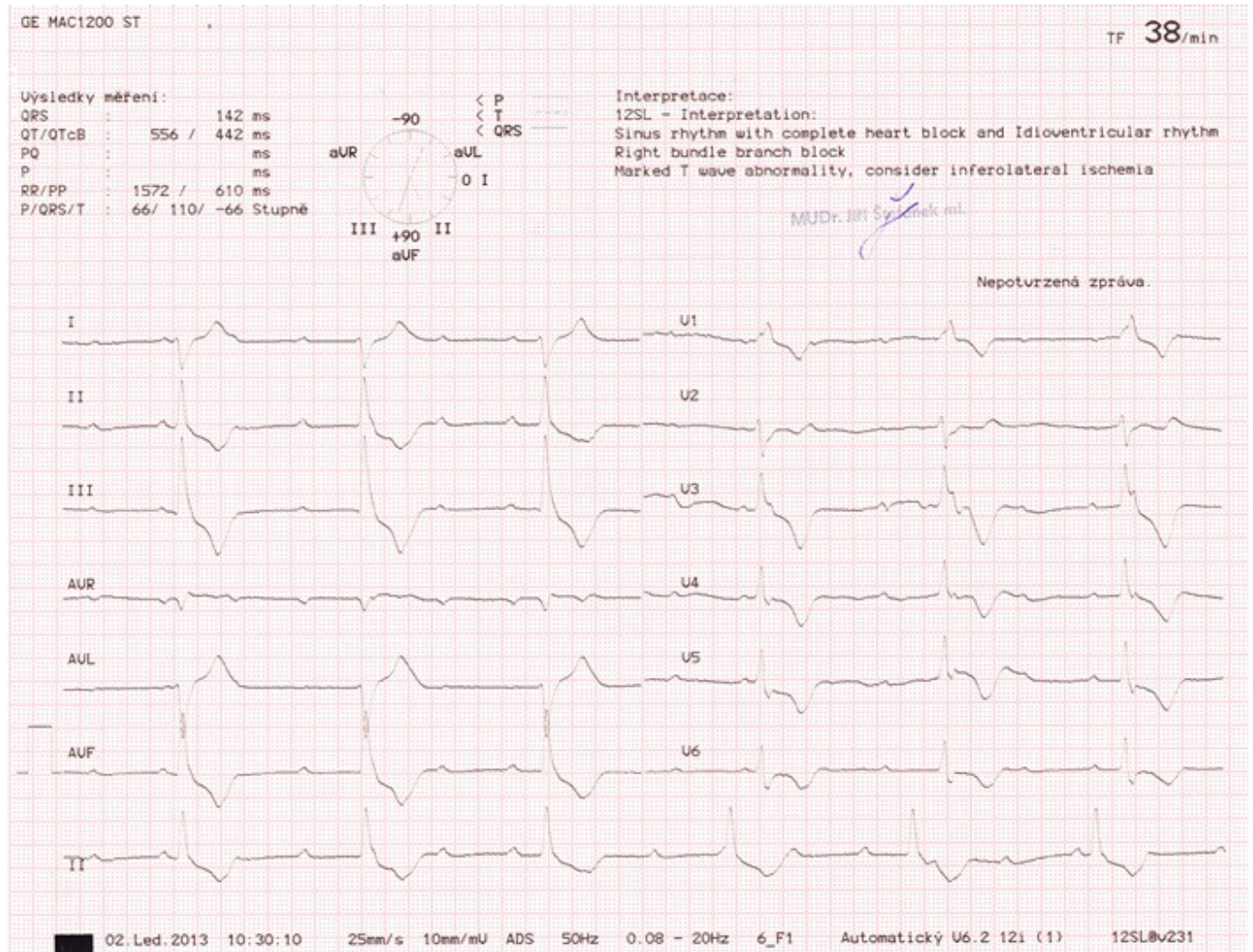


ECG Strip 26



A patient (male, 82 years of age) has been sent by his general practitioner already with the right diagnosis. The ECG shows us [RBBB](#) and bradycardia. By a closer look we see P waves that are regular but completely independent on QRS complexes. Therefore, this is a typical [third-degree AV block](#).